



Effects of Sidr honey on second-intention healing of contaminated full-thickness skin wounds in healthy dogs

Wael M. Hananeh¹, Zuhair Bani Ismail², Musa A. Alshehabat²,
Mahmoud Abu Abeeleh³, Ja'far Hasan Ali²

¹Department of Pathology and Public Health,

²Department of Veterinary Clinical Sciences;

Faculty of Veterinary Medicine, Jordan University of Science and Technology, Irbid 22110, Jordan

³Faculty of Medicine, University of Jordan, Amman 11942, Jordan

whananeh@just.edu.jo

Received: May 3, 2015

Accepted: September 14, 2015

Abstract

The therapeutic effects of Sidr honey on second-intention healing of contaminated full-thickness skin wounds in dogs were investigated. Povidone-iodine was used as a standard treatment and served as a control. Healthy adult (two-to-four-year-old) mongrels, comprising six dogs and two bitches, were divided into four equal groups in order to obtain multi-aged wounds at the end of the study. Four 2cm × 2cm full-thickness skin wounds were created on both sides of the back area of each dog under general anaesthesia adhering to aseptic technique. Contaminated wounds were then divided into two treatment groups: Group 1, Sidr honey treated (right side wounds) and group 2, povidone-iodine treated (left side wounds). All wounds were evaluated grossly daily at the time of treatment application and digitally photographed once every week. Images were analysed using ImageJ software. The parameters of unhealed wound area and length of advancing epithelium were obtained. The epithelialisation areas, percentage of wound area, and wound contraction rate were then calculated. No significant differences were found between the two treatment groups in any of the parameters studied. Overall, both honey treated and iodine treated wounds healed well within the time period of the study (28 d). However, the study showed a beneficial effect of Sidr honey on second-intention healing of full thickness contaminated wounds in healthy dogs and the effect was comparable to that of Povidone iodine.

Keywords: dogs, Sidr honey, povidone-iodine, wounds, wound healing.

Introduction

Honey has been used as a wound care remedy since ancient times (12). The Egyptians (2600-2200 BC) were the first to apply honey to wounds (12). Since then, the use of honey for the treatment of wounds as well as honey's use exploiting many other of its medicinal attributes has been under scientific scrutiny.

Many medical properties have been attributed to honey. These include antibacterial, antifungal, antiviral, anti-inflammatory, antioxidant, anti-tumour, anti-mutagenic, and prebiotic properties (17). There were no adverse effects on tissues related to honey use. On the contrary, activity was shown superior to several modern wound care products (23).

Various honey-based wound healing products are available in the market today that are approved for human use. Such products have gained popularity due to rising bacterial resistance against common antibiotics and to the need to overcome clinical difficulties in management of chronic wounds (9). In veterinary practice, there is an obvious demand for products that enhance wound healing and provide potent antibacterial activity (19).

Among various types of honey around the world, two medical grade honeys, Revamil source (RS) honey and Manuka honey have been approved for use in wound management due to their various medicinal features, especially the broad spectrum of antibacterial properties (14). Revamil source is produced in greenhouses under controlled

environmental conditions (14). Several factors were found to be responsible for the bactericidal activity of this honey including its high concentration of sugar, H₂O₂, 1, 2-dicarbonyl compound methylglyoxal (MGO), cationic antimicrobial peptide bee defensin-1, and the low pH (14). Manuka honey is of particular interest due to its superior antibacterial activity, which acts independently of the peroxide activity and osmolality (16). Methylglyoxal was found to be responsible for the majority of bactericidal activity in Manuka honey (16, 2).

Sidr honey is considered one of the finest original honeys produced in the Arabic countries. The honey has been successfully used for the treatment of various health problems such as gastric ulcers, liver diseases, and respiratory disorders in humans as well as various disorders in rat models. Furthermore, the phytochemical components of this honey were accounted responsible for its remarkable analgesic, anti-inflammatory, and antipyretic effects (4).

Although wound-healing effects of sundry types of honey have been investigated, including natural honey and commercially-produced honey-containing products, no scientific or clinical reports in recent literature can be found about the possible therapeutic effects of Sidr honey on second-intention healing of contaminated wounds. Therefore, the objective of this study was to evaluate the effects of Sidr honey on second-intention healing of contaminated full-thickness skin wounds in healthy dogs.

Material and Methods

Experimental animals. A total of eight (six males and two females), two- to four-year-old, healthy mongrel dogs weighing 20 ± 5 kg were used. A complete physical examination and blood analysis were performed prior to the initiation of the study. Upon their arrival at the Veterinary Health Center at Jordan University of Science and Technology, animals were assigned to separate cages, allowed free access to water, and fed a standard locally-manufactured dry dog diet. The dogs were allowed to acclimatise for 10 d prior to the study. During acclimatisation they were vaccinated against rabies (Biocan, Bioveta, Czech Republic) and treated against parasitic diseases (Droncit, Bayer Animal Health, USA). Rectal temperature, respiration, and heart rates (TRP) were recorded weekly.

Wound creation and treatment protocols. Prior to general anaesthesia, the dogs were clinically examined and pre-medicated with an intramuscular injection of 2% xylazine hydrochloride (Xyla-Ject, Adwia, Egypt) at a dose of 1 mg/kg b.w. and a subcutaneous injection of 1% atropine sulphate (Adwia, Egypt) at a dose of 0.005 mg/kg b.w. 10% ketamine hydrochloride (Ketamina, Alfasan, Holland) was then given intramuscularly at a dose of

15 mg/kg b.w. to induce general anaesthesia. An approximately 15 cm × 15 cm area of the back on both sides of each animal was clipped and prepared for aseptic surgery. Four 2 cm × 2 cm full-thickness wounds, 5 cm apart were created on both sides of the animals' backs. Wound contamination was achieved by covering the entire surface of the wounds with 2 g of fresh dog faeces and bandaging for 24 h (6).

After 24 h wound dressings were removed and the wounds were flushed with sterile isotonic saline (0.9% NaCl). Thereafter, the wounds were divided into two treatment groups: group 1 - the right side wounds were treated with Sidr honey, N = 16; and group 2 - the left side wounds were treated with a 10% solution of Povidone-iodine, N = 16. In order to obtain multi-aged wounds at the end of the study, wounds were created in two dogs per week for four consecutive weeks, resulting in four groups of dogs.

Contaminated wounds on the right side of the animals' backs were treated topically using 1 to 2 mL of pure Sidr honey (Pure Sidr Honey, Al-Yahya Honey Factory, Kingdom of Saudi Arabia) and left uncovered to heal by second-intention. Contaminated wounds on the left side of the animals' backs received 1 to 2 mL of Povidone-iodine solution and served as control (HiGeen 10% Iodine, Households & Toiletries Mfg. Co., Jordan). Sidr honey was applied to each wound twice a day for one week and then once daily until the end of the study period (28 d). The same procedure was followed using Povidone-iodine.

Gross evaluation. Wounds were grossly evaluated twice a day during the first week and once daily for the rest of the study period. Observation was undertaken at the time of treatment application. The wounds were inspected for the presence of any signs of inflammation such as hyperaemia (redness), oedema, and type and degree of exudation. In addition, the following parameters were recorded: the day the initial granulation tissue was observed, the day the entire wound was covered by granulation tissue, the day of initial epithelialisation (if started within the study period), and the day the wound was completely epithelialised.

Analysis of digital imaging. Wounds were photographed once every week using a digital camera on days 0, 1, 7, 14, 21, and 28 of the study. A standard reference ruler was placed adjacent to the wound before obtaining photographs. Analysis of the digital images was made using image processing and analysis software (ImageJ, National Institutes of Health, USA). The unhealed wound area (cm²) and length of the advancing epithelium (mm) were measured four times to calculate the mean in order to obtain a single measurement for every wound on each observation day (Figs 1, 2).

Additionally, the epithelialisation area (cm²) was calculated by subtracting the measured unhealed wound area of a given day from the initial unhealed area of the same wound (day 0). The percentage of wound area

was then calculated for each wound using the following formula:

Wound area (%) = $100 \times (\text{wound area on day X}/\text{initial wound area})$ (13).

The wound contraction rate was calculated using the following formula:

Wound contraction rate = $100 \times (\text{initial wound area} - \text{area of the given wound at the evaluation time})/\text{initial wound area}$ (15).

Statistical analysis. The mean and standard deviation were calculated for the digital imaging parameters: unhealed wound area (cm²), epithelialisation area (cm²), the length of the advancing epithelium (mm), percentage of wound area, and the wound contraction rate for honey-treated wounds and iodine-treated wounds at the time points of days 0, 7, 14, 21, and 28. The data was presented as mean \pm standard deviation.

Student's independent t-test was used to find differences in the evaluated parameters between honey-treated and iodine-treated wounds on the appointed days. Repeated measure analysis of each of the evaluated parameters was performed using GLM repeated measure. Post-hoc pairwise comparisons were performed using the Bonferroni test.

Results

Gross evaluation. All animal groups treated with either pure Sidr honey or Povidone-iodine survived the surgical procedure. None of the animals experienced any major complications. All animals were in good body condition until the cessation of the entire experiment.

During week 1 of the study, in both groups, neither significant abnormalities nor differences were present in the surgical sites. No exudates were observed during the first 2 d after the surgery. However, mild exudates were noticed after then until the end of the first week. Wound oedema was seen during the entirety of week 1 and was more severe in the second half of

the same week. The initial granulation tissue was observed on day 6 of that week.

In honey-treated wounds, mild signs of inflammation disappeared during the first 2 to 3 d of week 2 (day 9 or 10 after surgery). Initial granulation tissue started to appear in the wound bed by the 6th day after surgery and appeared to fill it out by day 9 to 11. Initial epithelialisation started to appear on all wounds during days 11 to 14 after surgery.

In iodine-treated wounds, moderate to mild inflammatory signs appeared to persist further into week 2 while a pattern of granulation tissue and epithelialisation similar to that observed in honey-treated wounds was reported in this group of wounds.

By the beginning of week 3, honey-treated wounds appeared to have no apparent signs of inflammation. By contrast, in the wounds treated with iodine, a mild degree of hyperaemia and mild production of wound exudates persisted during the entire period of the second week and well into the third week. Wound contraction appeared to start in all wounds during this week.

During week 4 after surgery, no signs of inflammation were observed in either group. Wound contraction appeared to reduce the wound area substantially. Epithelialisation appeared to be completed by day 26 in the honey-treated group, whereas in the iodine-treated group, epithelialisation was completed by day 27.

Analysis of digital imaging. There were no statistically significant differences in any of the parameters (unhealed wound area, epithelialisation area, length of the advancing epithelium, percentage of wound area, and percentage of wound contraction) analysed between honey-treated and iodine-treated wounds. The means \pm SD of wound healing parameters for both treatment groups are presented in Table 1. Repeated measure analysis revealed a progressive significant difference in the examined parameter as the time progressed throughout the experiment for each treatment at days 14, 21, and 28 when compared to day 0.

Table 1. The means \pm SD of unhealed wound area, epithelialisation area, length of the advancing epithelium, wound area, and percentage of wound contraction in honey-treated and iodine-treated wounds

Group	Number of wounds	Time	Unhealed wound area (cm ²)	Epithelialisation area (cm ²)	Length of the advancing epithelium (mm)	Wound area (%)	Wound contraction (%)
Honey-treated							
	16	D0	3.94 \pm 0.18	--	--	100	--
	16	D7	3.14 \pm 0.6	0.91 \pm 0.61	--	79.76 \pm 15.8	22.76 \pm 14.88
	12	D14	1.77 \pm 0.81	2.19 \pm 0.76	4.03 \pm 0.9	44.47 \pm 19.82	55.52 \pm 19.82
	8	D21	0.48 \pm 0.31	3.40 \pm 0.37	5.40 \pm 0.93	12.54 \pm 7.95	87.45 \pm 7.96
	4	D28	0.14 \pm 0.13	3.84 \pm 0.19	7.36 \pm 1.11	3.58 \pm 3.49	96.41 \pm 3.49
Iodine-treated							
	16	D0	3.93 \pm 0.16	--	--	100	--
	16	D7	3.26 \pm 0.51	0.76 \pm 0.44	--	82.89 \pm 12.27	19.27 \pm 11.25
	12	D14	1.98 \pm 0.73	1.92 \pm 0.7	3.43 \pm 1.12	50.61 \pm 18.46	49.38 \pm 18.46
	8	D21	0.52 \pm 0.23	3.35 \pm 0.32	5.96 \pm 1.51	13.62 \pm 6.23	86.37 \pm 6.23
	4	D28	0.14 \pm 0.1	3.81 \pm 0.4	7.23 \pm 0.94	3.46 \pm 2.57	96.53 \pm 2.58

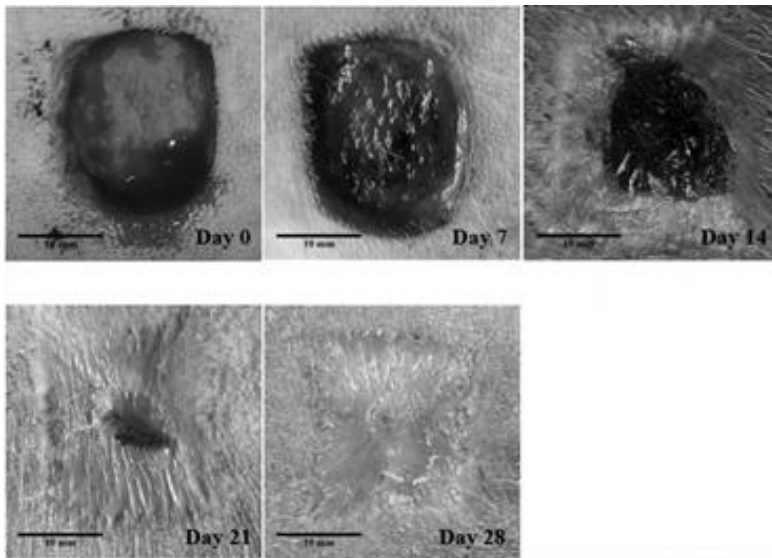


Fig. 1. Honey-treated wounds of the first group at different time points (0, 7, 14, 21, and 28 d) after surgery

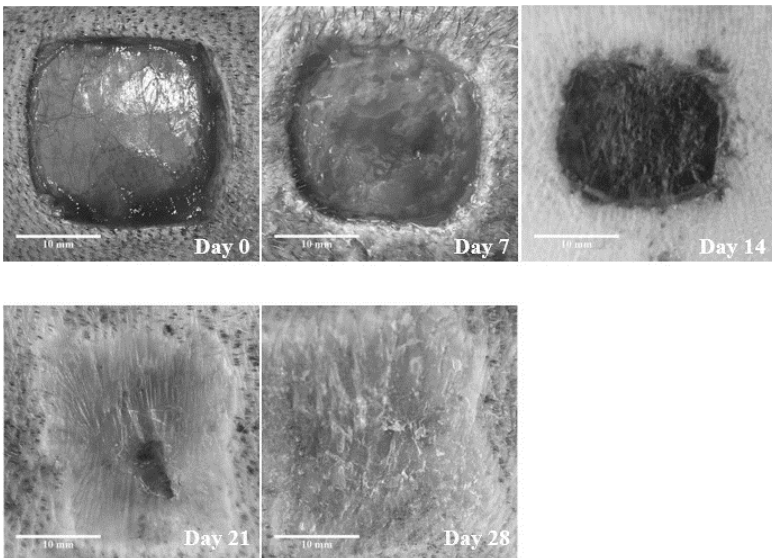


Fig. 2. Iodine-treated wounds of the first group at different time points (0, 7, 14, 21, and 28 d) after surgery

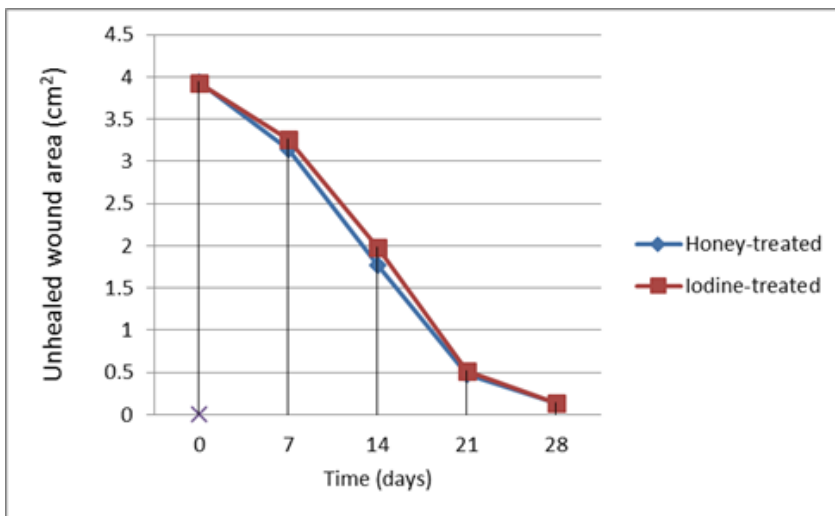


Fig. 3. The unhealed wound area in honey-treated and iodine-treated wounds

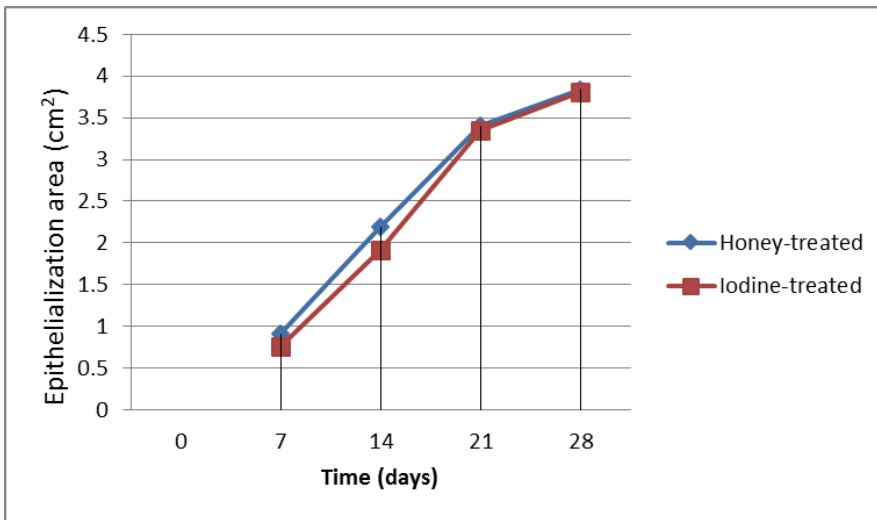


Fig. 4. The epithelialisation area in honey-treated and iodine-treated wounds

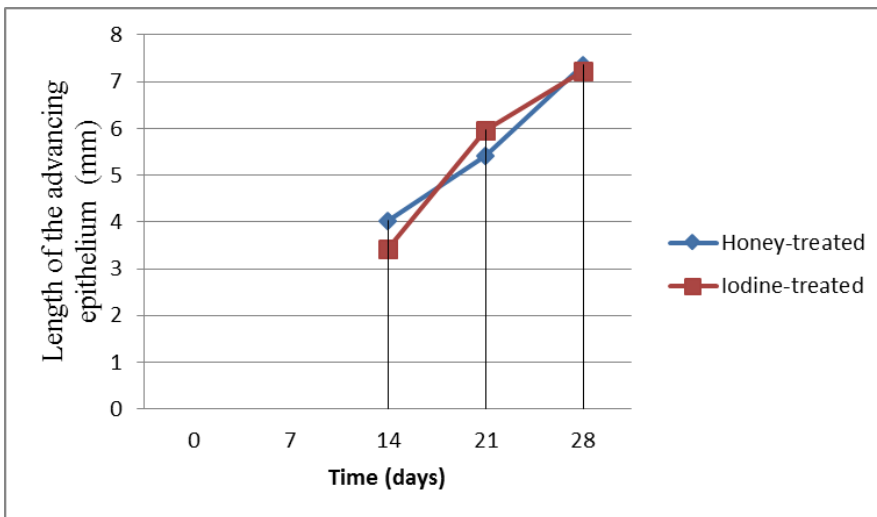


Fig. 5. The length of advancing epithelium in honey-treated and iodine-treated wounds

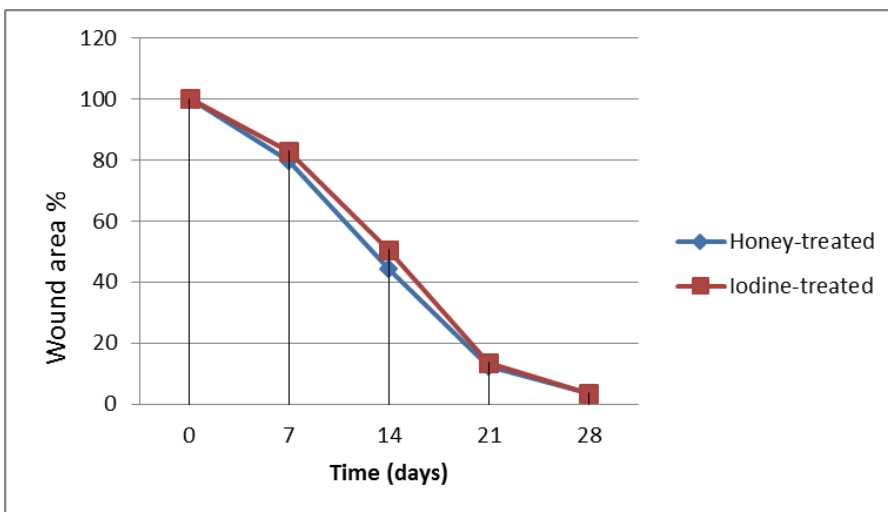


Fig. 6. The wound area in percentage in honey-treated and iodine-treated wounds

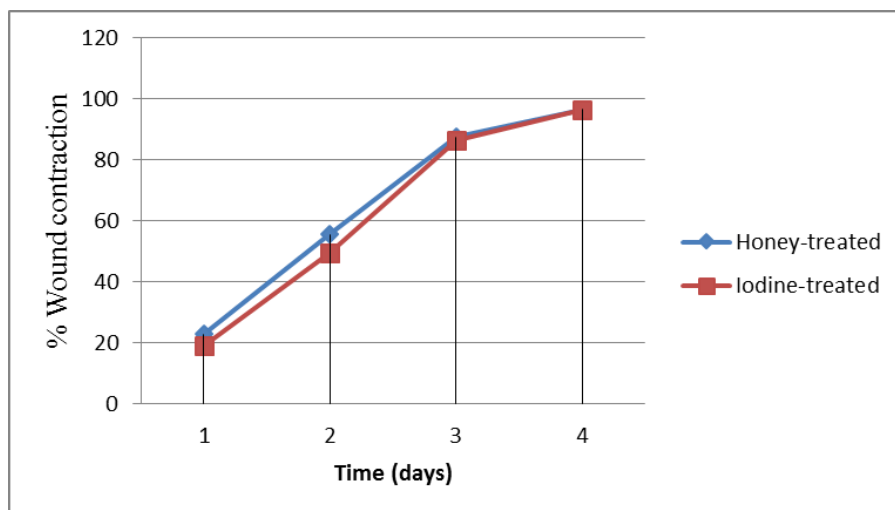


Fig. 7. The percentage of wound contraction in honey-treated and iodine-treated wounds

The means of different studied parameters were shown in Figs 3 - 7. Similar trends were noticed concerning all the studied parameters in both honey-treated and iodine-treated wounds at different time points: at days 0, 7, 14, 21, and 28. Figs 1 and 2 illustrate the measured unhealed wound area as well as the traced new epithelium (once it had appeared) for both treatment groups at different time points respectively.

Discussion

The therapeutic effects of honey have been described for centuries. Different types of honey exist; however, variation in medicinal properties is mainly attributed to the floral source of each honey. Topical application for wound treatment is a common procedure in human and veterinary medicine (22, 20). In the present study, the effect of Sidr honey on second-intention healing of contaminated wounds in dogs was investigated and compared to the effect of a standard wound topical agent (povidone-iodine).

In this study, a modified wound healing model was used (8, 1). Previously reported models were used for evaluation of healing of “non-contaminated” full-thickness wounds which were covered by a bandage. Moreover, wounds in this study were created on the back area of the dog. This animal model using the back to evaluate wound healing process is reported for the first time. Unlike previous research models, wounds in this study were experimentally contaminated, left without bandaging, and then healing was assessed daily for 28 d. Wounds on the back of the animal allowed for easy application of the drugs and easy monitoring while the same time they prevented the dog’s damaging the wounds and interrupting the process of healing by licking and scratching (7, 18, 11). Similar to previous reports, it appeared that 1 to 2 mL of Sidr honey were adequate to evaluate the healing effects on the wounds (8).

Treatment of wounds using topically applied medications is a common therapeutic approach (22, 20, 25). The use of honey as a topical treatment of wounds or as a wound dressing was found to enhance healing (1). Studies also demonstrated that topical application of honey for treatment of wounds resulted in stimulated tissue growth, enhanced granulation and epithelialisation, improved the wound’s tensile strength, and minimised tissue scarring (1). Moreover, honey was reported for its antibacterial (10), anti-inflammatory (3), antioxidant, (3) and a variety of other therapeutic properties that positively influence wound, burn, and ulcer healing processes (3). Sidr honey was reported for its anti-inflammatory, anti-pyretic, and analgesic effects (4).

No significant differences in wound contraction, healing, or epithelialisation between treatment groups were found in our study. Wounds treated with Sidr honey contracted as much as those treated with Povidone-iodine. In both groups, the mean values of unhealed wound area and wound area as a percentage, epithelialisation area, and the length of the advancing epithelium exhibited similar trends as measured on days 0, 7, 14, 21, and 28. Similar findings in comparison to either Chitosan gel or Hydrofiber silver were reported in previous studies using Taulang honey (24). Nonetheless, values of unhealed wound area in this study demonstrated that topical application of Sidr honey on full-thickness contaminated wounds created on the back area of dogs gave improvement in the healing process as indicated by variable reduction of the unhealed wound area in group 1 at the end of the fourth week, group 2 at the end of the third week, group 3 at the end of the second week, and in group 4 at the end of the first week. This result confirms the fact that topical application of honey enhances the healing of full-thickness wounds. Similarly, there have been several studies that documented this positive influence of honey on the rate of wound healing in different animal models (5). Previous studies have also revealed the superiority of

honey as a topical wound treatment when used alone, or when used mixed with other topical agents in several animal models (5).

Although in this study, the specific antibacterial effects of Sidr honey on total number and type of bacterial population on the wound surface were not determined, none of the wounds experienced overt signs of local infections such as abscess formation or draining tracts. In addition, minimal inflammatory signs were observed in the wounds treated by honey in this study. Neither were adverse local or systemic effects reported in any of the dogs treated with Sidr honey. The only limitation that is worth mentioning here is that once being applied to the wound, honey becomes less viscous and runs off the surface of the wound, making contact time shorter than desirable. This could be avoided by applying a bandage over the wound surface. However, a bandage was not used in this study because we intended to study uncovered wound healing. In future research, this problem could be overcome by the development of ointment containing Sidr honey.

In conclusion, the current study has shown a beneficial effect of Sidr honey on second-intention healing of full-thickness contaminated skin wounds in dogs. Wounds treated by Sidr honey healed as fast as those wounds treated by iodine. Further research is recommended to investigate the specific mechanism by which Sidr honey enhances wound healing, such as anti-inflammatory and antibacterial effects.

Conflict of Interests Statement: The authors declare that they have no conflict of interests regarding the publication of this article.

Animal Rights Statement: The study protocol has been reviewed and approved by the Jordan University of Science and Technology Animal Use and Care Committee (ACUC).

Acknowledgments: Deep thanks are extended to the Deanship of Research of the Jordan University of Science and Technology for their financial support.

References

- Abdel-Wahed R.E., El-Kammar M.H., Korittum A.S., Edrees I.R.: Surgical and histological evaluation of the effectiveness of propolis on wound healing. *Alexandria J Vet Sci* 2013, 39, 52–63.
- Adams C.J., Manley-Harris M., Molan P.C.: The origin of methylglyoxal in New Zealand manuka (*Leptospermum scoparium*) honey. *Carbohydr Res* 2009, 344, 1050–1053.
- Al-Waili N., Salom K., Al-Ghamdi A.A.: Honey for wound healing, ulcers, and burns; data supporting its use in clinical practice. *SciWorld J* 2011, 11, 766–787.
- Alzubier A., Okechukwu P.: Investigation of anti-inflammatory, antipyretic and analgesic effect of Yemeni Sidr Honey. *World Acad Sci Engin Technol* 2011, 5, 41–46.
- Bani Ismail Z., Alshehabat M., Hananeh W., Daradka M., Ali J., El-Najjar E.: Recent advances in topical wound healing products with special reference to honey: a review. *Res Opin Vet Sci* 2015, 5, 76–83.
- Bischofberger A.S., Dart C.M., Perkins N.R., Kelly A., Jeffcott L., Dart A.J.: The effect of short- and long-term treatment with manuka honey on second intention healing of contaminated and noncontaminated wounds on the distal aspect of the forelimbs in horses. *Vet Surg* 2013, 42, 154–160.
- Demir A., Şimsek T., Engin M.S., Yildiz L.: The effect of topical honey dressing on wound healing in diabetic mice. *Gazi Med J* 2007, 18, 110–113.
- Esmaelian B., Najafi O., Aldavood S.J., Jalali F.S.S., Farshid A.A., Rahmani S.: Clinical and histopathological evaluations of local honey application in the healing of experimental wounds in dog. *J Vet Res* 2012, 63, 265–271.
- Fischbach M.A.: Antibiotics from microbes: converging to kill. *Curr Opin Microbiol* 2009, 12, 520–527.
- Hammond E.N., Donkor E.S.: Antibacterial effect of manuka honey on *Clostridium difficile*. *BMC Res Notes* 2013, 6, 188.
- Hwisa N.T., Katakam P., Chandu B.R., Abadi E.G., Shefha E.M.: Comparative in vivo evaluation of three types of honey on topical wound healing activity in rabbits. *J Appl Pharm Sci* 2013, 3, 139–143.
- Jull A.B., Walker N., Deshpande S.: Honey as a topical treatment for wounds. *Cochrane Database Syst Re.* 2015 Mar 6;3: CD005083. doi: 10.1002/14651858.CD005083.pub4.
- Kandemir F.M., Sagliyan A., Ozkaraca M., Gunay C., Han M.C., Benzer F.: Effects of oral administrations of pomegranate seed extract on surgical wound healing in rabbits. *Revue Méd Vét* 2013, 164, 400–408.
- Kwakman P.H., Van den Akker J.P., Guclu A., Aslami H., Binnekade J.M., De Boer L., Boszhard L., Paulus F., Middelhoek P., te Velde A.A., Vandenbroucke-Grauls C.M., Schultz M.J., Zaat S.A.: Medical-grade honey kills antibiotic-resistant bacteria in vitro and eradicates skin colonization. *Clin Infect Dis* 2008, 46, 1677–1682.
- Marques S.R., Peixoto C.A., Messias J.B., De Albuquerque A.R., Silva Junior V.A.: The effects of topical application of sunflower-seed oil on open wound healing in lambs. *Acta Cirurg Brasil* 2004, 19, 196–209.
- Mavric E., Wittmann S., Barth G., Henle T.: Identification and quantification of methylglyoxal as the dominant antibacterial constituent of manuka (*Leptospermum scoparium*) honeys from New Zealand. *Mol Nutr Food Res* 2008, 52, 483–489.
- Molan P.C.: The evidence and the rationale for the use of honey as a wound dressing. *Wound Pract Res* 2011, 19, 204–221.
- Nisbet H.O., Nisbet C., Yarim M., Guler A., Ozak A.: Effects of three types of honey on cutaneous wound healing. *Wounds* 2010, 22, 275–283.
- Overgaauw P.A., Kirpensteijn J.: Honey in treatment of skin wounds. *Tijdschr Diergeneesk* 2005, 130, 115–116.
- Sarabahi S.: Recent advances in topical wound care. *Indian J Plast Surg* 2012, 45, 379–387.
- Sazegar G., Seyed Reza A.H., Behravan E.: The effects of supplemental zinc and honey on wound healing in rats. *Iran J Basic Med Sci* 2011, 14, 391–398.
- Stojadinovic A., Carlson J.W., Schultz G.S., Davis T.A., Elster E.A.: Topical advances in wound care. *Gynecol Oncol* 2008, 111, 70–80.
- Subrahmanyam M.: Topical application of honey for burn wound treatment - an overview. *Ann Burns Fire Disasters* 2007, 20, 137–139.
- Sukur S.M., Halim A.S., Singh K.K.: Evaluations of bacterial contaminated full thickness burn wound healing in Sprague Dawley rats treated with Tualang honey. *Indian J Plast Surg* 2011, 44, 112–117.
- Tang J., Liu H., Gao C., Mu L., Yang S., Rong M., Zhang Z., Liu J., Ding Q., Lai R.: A small peptide with potential ability to promote wound healing. *PLoS One* 2014 e92082. doi: 10.1371/journal.pone.0092082.

